

Preliminary Results of the Study of Animal Remains from the Site of Shahr-i Sokhta, Iran: New Research

Claudia Minniti

Università del Salento, Dipartimento di Beni Culturali

1. Introduction

2017 saw the start of the study of the animal remains from the site of Shahr-i Sokhta (Iran) that were collected in the course of the excavation campaigns conducted by the Iranian Archaeological Mission from 1997 onwards, as an integral part of the Multidisciplinary International Archaeological Project in Shahr-i Sokhta (MAIPS) headed by the University of the Salento (Lecce). The aim was to investigate the exploitation of animals at the site during the period from the 4th to the 2nd millennia BC via the analysis of animal remains, with a view to obtaining a better understanding of the local environment, the economy of the settlement (including animal husbandry and the role of the main domestic and wild species) and the diet of the inhabitants.

2. Materials and methods

The archaeo-zoological analyses in Shahr-i Sokhta were first applied to the animal remains from *Building 1*, located in the so-called Monumental Area of the site (Sajjadi - Moradi 2014). They constituted an ideal sample of fauna due to

both the continuity of use of the building from Period II to Period III of the site and the large quantity of bone materials that it provided. This paper presents some preliminary results.

The study of the animal finds was conducted in accordance with the traditional methods of the discipline. For the scientific nomenclature of the domesticated animals, reference was made to Gentry *et al.* (2004). The distinction between sheep and goat is based on the observations of Boessneck *et al.* (1964) concerning anatomical features (humerus, radius, metapodials, astragalus, calcaneus, phalanges); Kratochvil (1969) for the distal tibia; Payne (1985) for the lower deciduous teeth; and Halstead - Collins (2002) for the lower permanent teeth. The age of death was determined on the basis of the fusion of the articular epiphyses, in accordance with the methods proposed by Silver (1969) for cattle and by Bullock - Rackham (1982) for caprines. Tooth wear stages were assessed with reference to Payne (1973; 1987) for caprines and Grant (1982) for cattle. Bone measurements were performed in accordance with the methods indicated by von den Driesch (1976) and Davis (1992), although they are not discussed here.

In this early phase of the work, just over 1400 animal finds were identified to the level of the species, anatomical feature, age and sex. Small fragments were classified as non-identifiable. Ribs and vertebrae were sorted into three size categories: large (cattle), medium (caprines) and small (hare).

Most of the animal remains were found in an excellent state of conservation, which enables the recovery of fragile tissues such as the keratin encasing the horn. Many traces of gnawing by both carnivores and rodents were observed. The high incidence of these traces suggests that the burial of the materials was a slow process.

3. Preliminary results

The animal remains analysed belong above all to mammals. The other classes of animal such as birds account for a much smaller quantity of remains. Among the domestic species identified were humped cattle (*Bos taurus indicus*), sheep (*Ovis aries*), goat (*Capra hircus*) and dog (*Canis familiaris*). The wild species

included urial (*Ovis orientalis*), wild goat (*Capra aegagrus*), roe deer (*Capreolus capreolus*), red deer (*Cervus elaphus*), gazelle (*Gazella* sp.), jackal (*Canis aureus*), mongoose (*Herpestes edwardsi*), long-eared hedgehog (*Hemiechinus* sp.), Indian gerbil (*Tatera indica*) and various birds not yet identified to species level (Tab. 1).

Sheep and goats are the predominant domestic species, followed by cattle; the wild species account for a smaller proportion of the remains.

The composition of the sample analysed to date is consistent with the results obtained by previous studies performed on the animal remains discovered during the excavation campaigns conducted by the Italian Archaeological Mission from 1967 to 1977 (Bökönyi - Bartosiewicz 2000).

Caprines represent the dominant category of domestic animals, accounting for 82%. Sheep are slightly more numerous than goats, accounting for 56% of the caprines identified to species level. The broad variety of sheep horn cores already

	NISP	%
Cattle	233	16.4
Sheep or goat	551	38.9
Sheep	268	18.9
Goat	213	15.0
Dog	4	0.3
Red deer	6	0.4
Roe deer	3	0.2
Urial	14	1.0
Wild goat	8	0.6
Gazelle	67	4.7
Jackal	4	0.3
Mongoose	7	0.5
Hedgehog	11	0.7
Rodents	3	0.2
Indian gerbil	1	0.1
Birds	25	1.8
Total	1418	

Tab. 1: number of Identified Specimens (NISP) by species, with relative percentage.

observed in previous studies is confirmed by the new data (Bökönyi - Bartosiewicz 2000: 120). Specimens with short and straight horn cores (turbary) and wide and twisted horn cores (copper) were identified, but to date no specimens of zackel horn cores have been recorded.

The contribution of game animals to the food supply was marginal. The presence of urial, wild goat, red deer, roe deer and above all gazelle has been documented by previous studies (Table 2). The identification of some species, such as red deer, is particularly important for understanding the environment of the settlement. A forest environment typical of red deer probably characterised the area not far from the site. Regarding gazelles, a small specimen that might correspond to the mountain gazelle (*Gazella gazella*), already documented by previous studies (Bökönyi - Bartosiewicz 2000), was identified. However, the new data are still insufficient to exclude the presence of the Persian gazelle (*Gazella subgutturosa*), identified in Shahr-i Sokhta by Compagnoni (1978).

Other wild species identified include the small Asian mongoose, and the long-eared hedgehog. The mongoose lives in scrublands and dry forest, whereas the long-eared hedgehog prefers dry river valleys, gullies, riparian forest, abandoned irrigation ditches and shrubby areas.

Albeit on a purely preliminary basis, the new data seem to confirm the absence of wild and domestic pigs among the animal remains discovered in Shahr-i Sokhta, as suggested by analyses of material from the Italian excavations (Bökönyi - Bartosiewicz 2000: 124). This finding is not consistent with either the presence of numerous clay figurines of pigs or the presence of marshy habitats, forests with dense undergrowth and reed beds, as indicated by the archaeobotanical analyses (Costantini 1979).

The mortality data obtained from the analysis of the epiphyseal fusion of the bones show that the majority of the caprines were slaughtered at least four years of age, with a small part of the remains belonging to animals killed between the first and fourth year of age (Tab. 3). Tooth wear stage data confirm these results, showing that about 30% of the caprines were killed from the first to the fourth year of age and that most of the animals were killed at a mature age.

Taxon	NISP	%
Red deer	6	4
Roe deer	3	2
Urial	14	9
Wild goat	8	5
Gazelle	67	45
Jackal	4	3
Mongoose	7	5
Hedgehog	11	7
Rodents	3	2
Indian gerbil	1	1
Birds	25	17
Total	149	

Tab. 2: Number of identified Specimens (NISP) of wild species, with relative percentage.

The results obtained suggest that most of the caprines were butchered after having been extensively used for secondary products (mainly wool), while a smaller group were killed for the direct consumption of their meat (Fig. 1). These data appear to be consistent with the presence of a textile workshop in *Building 1* and with the documented presence of wool fibres and various objects associated with craft textile production (Sajjadi - Moradi 2014). However, this scenario is broadly susceptible to change as the study of animal materials is still ongoing.

Examining the data on epiphyseal fusion in cattle, a high percentage of animals are killed from the first to the fourth year of age, with just 30% of the animals killed after the fourth year of age (Tab. 4). This suggests that the livestock was mainly exploited for meat and only secondarily for the production of milk and as beasts of burden.

4. Burial of a macaque (Tomb 9319)

Discovered in the 2017 excavation campaign on the western edge of square NFA in the central part of the necropolis was a burial of a macaque (Fig. 2). In the same area there were also forty-six human graves, mainly dated to Period II of the site (Minniti - Sajjadi 2019).

	Age	NF	For
Humerus d.	-12 months	0	53
Radius p.	-12 months	0	35
Coxae a.	-12 months	1	45
Scapula d.	12 months	6	25
Phalanx 1 p.	14-35 months	2	49
Phalanx 2 p.	14-35 months	0	19
Tibia d.	35 months	8	39
Femur p.	35 months	11	13
Femur d.	48 months	6	7
Metacarpal d.	48 months	2	32
Metatarsal d.	48 months	5	6
Metapodial d.	48 months	4	3
Tibia p.	48 months	3	8
Humerus p.	48-60 months	1	3
Radius d.	48-60 months	8	8
Ulna p.	48-60 months	3	3
Calcaneus p.	48-60 months	8	19

Tab. 3: frequencies of unfused (NF) and fused (F) bones of caprines (p. = proximal, d. = distal, a = acetabulum). Age categories in accordance with Bullock – Rackham (1982).

The animal was identified as belonging to the Asiatic species *Macaca mulatta* (Zimmermann, 1780) from the upper and lower dental arches with reference to Swindler (2002), and by comparison with photographs of the skulls and jawbones of various species from the reference collection kept in the National Museum of Natural History in Pretoria, South Africa. It was distinguished from the tailless Barbary macaque (*Macaca sylvanus* L.), the only species of macaque to inhabit North Africa, which could have arrived in Shahr-i Sokhta from Egypt, by the presence of several post-sacral vertebrae (four proximal vertebrae and four transitory or distal vertebrae were recorded) in accordance with Russo (2015).

The animal was buried in a simple oval-shaped pit. The skeleton lay on the right side with its body and legs stretched out, and the arms extending forwards, on an east-west axis. Near the skull was an unpainted pear-shaped beaker dated to Period II on the basis of its shape and the paste and temper of the pottery (Buson - Vidale 1984).

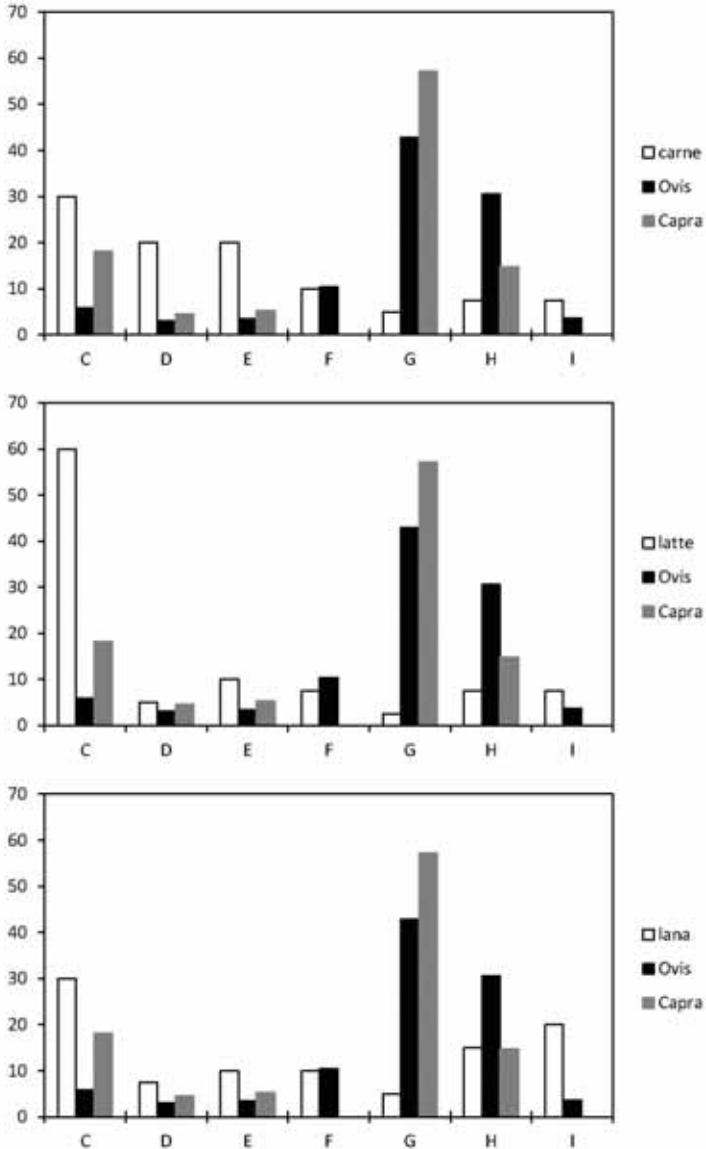


Fig. 1: mortality data for caprines in accordance with the age categories in Payne (1973), compared with ideal values when exploiting the animals for meat, milk and wool (A = 0-2 months; B = 2-6 months; C = 6-12 months; D = 12-24 months; E = 24-36 months; F = 36-48 months; G = 48-72 months; H = 72-96 months; I = 96-120 months).

	Age	NF	F
Scapula d.	7-10 months	1	3
Pelvis a.	7-10 months	0	3
Humerus d.	12-18 months	0	3
Radius p.	12-18 months	1	5
Phalanx 1 p.	18 months	1	14
Phalanx 2 p.	18 months	0	21
Metacarpal d.	24-30 months	1	3
Tibia d.	24-30 months	2	3
Metatarsal d.	24-36 months	2	2
Metapodial d.	30-36 months	2	0
Calcaneus p.	36 months	5	4
Femur p.	42 months	4	2
Humerus p.	42-48 months	2	0
Radius d.	42-48 months	5	3
Ulna p.	42-48 months	1	0
Femur d.	42-48 months	2	1
Tibia p.	42-48 months	2	

Tab. 4: frequencies of unfused (NF) and fused (F) bones of cattle (p. = proximal, d. = distal, a = acetabulum). Age categories in accordance with Silver (1969).

Although the skeleton was found complete and the bones still connected, the state of conservation was poor due to the crystallisation of salts on the surface. The skull and bones at the extremities of the limbs were badly damaged. No sign of combustion was found. Of particular interest is the fact that the macaque was buried in a tomb used mostly for children (Sajjadi 2014: 670), perhaps because of the animal's young age. The age of death is suggested by the stage of epiphyseal fusion and the dental eruption pattern. On the basis of Cheverud (1981), the macaque was determined to be about 5 years old at death. The teeth erupt about 6 months earlier in females than males (Fooden 2000: 39), and the timing of dental eruption and epiphyseal fusion of the skeleton found in the specimen seem to coincide with that of a male. However, no baculum was found and it is not known whether this absence is due to preservation or recovery factors. In the middle third of the diaphysis, on the posterior lateral side, cuneiform and tubular calcified formations growing in a proximal direction were observed on the surface of both



Fig. 2: burial of a rhesus macaque (tomb 9319).

femurs, probably representing calcification of the tendon or muscle insertion. This could be interpreted as a by-product of bone regeneration in response to skeletal injury. A similar condition affecting the diaphysis of both femurs was recently observed in a 6-year-old Javan macaque (*Macaca fascicularis* L.), raised in captivity in the Korean National Primates Research Centre. In this case, histological analysis showed that these anomalous bone formations had been produced by rapid bone regeneration of fractures (Lee *et al.* 2008; Hamada *et al.* 2012; Pritzker - Kessler 2012: 666).

The area of Shahr-i Sokhta does not lie within the natural range of any non-human primate species. Rhesus macaques inhabit central, southern and south-eastern Asia, all to the east of Sistan-Baluchistan (Fooden 2000: 2-7; fig. 21).

It may be readily surmised that the macaque found in Shahr-i Sokhta was brought from the valley of the Indus. Several finds from the site document contacts between the cultures of the Oxus, Jiroft, Hirmand and Indus in the third millennium BC (Cortesi *et al.* 2008; Jarrige *et al.* 2011; Moradgholi - Srivastav 2017). On the basis of Cortesi *et al.* (2008), these relations seem to reflect sporadic contacts, marriages and individual exchanges rather than systematic and specialised forms of long-distance commerce. However, increasing evidence suggests a more nuanced system of relations that gave rise to a process of cultural syncretism between Sistan and the other cultures of the Middle East (Ascalone 2016).

Although no other macaque or monkey species have ever inhabited the Near East or Mesopotamia, they were certainly well known in antiquity. Their presence in the Near East is attested in written sources, as well as seals, plaques and statuettes dated to a period from the 4th to the 2nd millennia BC. The most famous have already been analysed in detail (Dunham 1985; Collins 2002; Greenlaw 2011; Dotan - Regev 2011). A careful analysis of the sources has demonstrated that monkeys were generally considered symbols of prosperity and power, being rare animals, and often were presented as gifts to royalty. In written

texts they were usually listed together with other exotic animal species. They were typically kept as pets, sometimes chained (Dunham 1985: 265, fig. 1). In some cases they were depicted with human features (Dunham 1985: 265, fig. 10), dancing or playing the flute (Dunham 1985: 265, fig. 8), although Sumerian texts use the term monkey pejoratively (Dunham 1985: 242-244). It is also possible that monkeys were used in medical practices, as it was believed that their hairs and bones had curative or magic powers (Dunham 1985: 251).

Some species of monkey may have been imported from Egypt. Representations of non-human primates were certainly common in Egypt during the third millennium, spreading from here throughout the Mediterranean. An example is the statuette of a baboon found in the settlement of El Miqne-Ekron in Israel, dated to the 13th or 12th century BC (Dotan - Regev 2011). It probably represents the sacred baboon (*Papio hamadryas* L.) originating from North Africa and associated with the divinity of the moon. Most representations of primates from the Levant are not easily identifiable to the species level, although there are exceptions (Masseti in print). An example is the small red limestone statuette of a seated monkey found in Susa (Iran), dated to the third period (3100 - 2900 BC), with the characteristics of a rhesus macaque (Aruz 1992: 97, pl. 61).

Discoveries of remains of non-human primates in the Near East are rare. At the moment, some remains, identified as belonging to Barbary macaques and thus plausibly imported from Egypt, are documented in the settlement of Tell Rad Shaqrah (northern Syria), dated to the Early Dynastic Period (2500 - 2300 BC) (Piątkowska - Koliński 2015).

More recently, an incomplete skull of a new extinct species of gibbon was found in a tomb dated to about 2200 years ago in the ancient Chinese capital of Chang'an (Gabbatiss 2018). In contrast, the skull and jawbone of a young Barbary macaque discovered in Constantinople during the excavation of the Theodosius Gate near Yenikapı (Onar *et al.* 2013) are dated to the Byzantine period.

Bibliography

- Aruz, J., 1992. Figure of a seated monkey. In P.O. Harper, J. Aruz, and F. Tallon (ed.), *Royal city of Susa: ancient Near Eastern treasures in the Louvre*. The Metropolitan Museum of Art, New York.
- Ascalone, E., 2016. *An Integrated Cultural System among civilizations. Jiroft, Oxus and Elam between the half of Third and the beginning of Second Millennium BC*. Paper presented at the Conference of the National Museum of Iran, Tehran, 9 April 2016.
- Boessneck, J., Müller, H.-H., and M. Teichert, 1964. Osteologische Unterscheidungsmerkmale zwischen Schaf (*Ovis aries* L.) und Ziege (*Capra hircus* L.). *Kühn Archiv* 78, 1-129.
- Bökönyi, S., and L. Bartosiewicz, 2000. A review of animal remains from Shahr-i Sokta (eastern Iran). In M. Mashkour, A.M. Choyke, H. Buitenhuis, and F. Poplin (eds.), *Archaeozoology of the Near East IVB*. Proceedings of the fourth international symposium on the archeozoology of southwestern Asia and adjacent areas, ARC, Groningen, 116-152.
- Bullock D., and J. Rackham, 1982. Epiphyseal fusion and tooth eruption of feral goats from Moffatdale, Dumfries and Galloway. In B. Wilson, C. Grigson and S. Payne (eds.), *Ageing and sexing animal bones from archaeological Sites*. BAR British Series, 109, Oxford, 73-80.
- Cheverud, J.M., 1981. Epiphyseal union and dental eruption in *Macaca mulatta*. *American Journal of Physical Anthropology* 56, 157-167.
- Collins, B.J. (ed.), 2002. *A history of the animal world in the ancient Near East*. Handbook of Oriental Studies: Sect. 1, The Near and Middle East, Vol. 64, Leiden-Boston-Köln.
- Compagnoni, B., 1978. The Bone Remains of *Gazella subgutturosa* from Shahr-i Sokhta. In R.H. Meadow and M.A. Zeder (eds.), *Approaches to Faunal Analysis in the Middle East*. Peabody Museum Bulletin 2, 119-128.
- Cortesi, E., Tosi, M., Lazzari, A., and M. Vidale, 2008. Cultural relationships beyond the Iranian Plateau: the Hirmand civilization, Baluchistan and the Indus Valley in the 3rd millennium BC. *Paléorient* 34/2, 5-35.
- Costantini, L., 1979. Wood remains from Shahr-i Sokta: a source of information for the ancient environment in protohistoric Sistan. In M. Taddei (ed.), *South Asian Archaeology 1977*, Vol. 1. Seminario di Studi Asiatici 6, Napoli, 87-122.
- Davis, S.J.M., 1992. *A rapid method for recording information about mammal bones from archaeological sites*, AML Report 19/92.

- Dothan, T., and D. Regev, 2011. An inscribed baboon statuette from Tel Mique-Ekron. Egypt and the Levant. *International Journal for Egyptian Archaeology and Related Disciplines* 11, 211-230.
- Driesch, von den, A., 1976. *A guide to the measurements of animal bones from archaeological sites*, Peabody Museum Bulletin 1, 1-137.
- Dunham, S., 1985. The monkey in the middle. *Zeitschrift für Assyriologie und Vorderasiatische Archäologie* 75/2, 234-264.
- Fooden, J., 2000. *Systematic review of the Rhesus macaque, Macaca mulatta (Zimmermann, 1780)*. Fieldiana. Zoology, New Series 96, Field Museum of Natural History, Chicago.
- Gabbatiss, J., 2018. *New species of extinct ape discovered in tomb of ancient Chinese noblewoman*. Independent, 21 June 2018. <https://www.independent.co.uk/news/science/junzi-imperialis-ape-extinct-gibbon-china-ancient-tomb-xian-changan-a8410671.html>.
- Gentry, A., Clutton-Brock, J., and C.P. Groves, 2004. The Naming of Wild Animal Species and their Domestic Derivatives. *Journal of Archaeological Science* 31, 645-651.
- Grant, A., 1982. The use of tooth wear as a guide to the age of domestic ungulates. In B. Wilson, C. Grigson and S. Payne (eds.), *Ageing and sexing animal bones from archaeological Sites*. BAR British Series, 109, Oxford, 91-108.
- Greenlaw, C., 2006. Monkeying around the Mediterranean: a fresh perspective on ancient primates. In J. Day, C. Greenlaw, H. Hall, A. Kelly, L. Matassa, K. McAleese, E. Saunders and D. Stritch (eds.), *Soma 2004. Symposium on Mediterranean Archaeology*. BAR International Series, 1514, Oxford, 63-69.
- Halstead, P., and P. Collins, 2002. Sorting the sheep from the goats: morphological distinctions between the mandibles and mandibular teeth of adult Ovis and Capra. *Journal of Archaeological Science* 29, 545-553.
- Hamada, Y., Sawada, J., Cho, F., Won, M.-H., and B.-H. Hyun, 2012. Tubular anomalous bones found in both thighs of a long-tailed macaque (*Macaca fascicularis*). *Primates* 53, 25-30.
- Jarrige, J.-F., Didier, A., and G. Quivron, 2010. Shahr-i Sokhta and the chronology of the Indo-Iranian regions. *Paléorient* 37/2, 7-34.
- Lee, J.I., Kim, Y.S., Kim, M.J. and S.H. Hong, 2008. Idiopathic new bone formation in the femoral shafts of a cynomolgus monkey (*Macaca fascicularis*). *Journal of American Association for Laboratory Animal Science* 47, 68-71.
- Masseti, M., in press. Monkeys in the ancient Near East from prehistory to the first Islamic caliphate, in *History of primatology*, Oxford/New York.

Moradgholi, Z., and O.P. Srivastav, 2017. Investigation of geometric drawings on pottery of the ancient sites of the Shahr-i Sokhta (Iran) and comparison with similar samples in the northern Indian civilization. *EPRA International Journal of Economic and Business Review* 5/12, 16-22.

Onar, V., Alpak, H., Pazvant, G., Armutak, A., Gezer Ince, N., and Z. Kiziltan, 2013. A bridge from Byzantium to modern day Istanbul: an overview of animal skeleton remains found during Metro and Marmaray excavations. *Journal of the Faculty of Veterinary Medicine at Istanbul University* 39, 1-8.

Payne, S., 1973. Kill-off Patterns in Sheep and Goats: the Mandibles from Asvan Kale. *Anatolian Studies* 33, 281-303.

Payne, S., 1985. Morphological distinctions between the mandibular teeth of young sheep, Ovis, and goats, Capra. *Journal of Archaeological Science* 12, 139-147.

Payne, S., 1987. Reference Codes for Wear States in the Mandibular Cheek Teeth of Sheep and Goats. *Journal of Archaeological Science* 14, 609-614.

Piatkowska, J., and M.R. Koliński, 2015. The animal economy of people living in the settlement of Tell Rad Shaqrah (Syria). *Polish Archaeology in the Mediterranean* 24/1 (Research), 675-692.

Pritzker, K.P.H., and M.J. Kessler, 2012. Arthritis, Muscle, Adipose Tissue, and Bone Diseases of Nonhuman Primates. In C.R. Abee, K. Mansfield, S. Tardif and T. Morris (eds.) *Nonhuman Primates in Biomedical Research: Diseases*. Elsevier Inc.: Academic Press, 629-697.

Russo, G., 2015. Postsacral vertebral morphology in relation to tail length among primates and other mammals. *The Anatomical Record* 298, 354-375.

Sajjadi, S.M.S., 2014. Some Preliminary Observations from the New Excavations at the Graveyard of Shahr-I Sokhta. In C.C. Lamberg-Karlovsky, B. Genito, B. Cerasetti and M. Tosi (eds.), *My Life is like the Summer Rose. Maurizio Tosi e l'archeologia come modo di vivere*. Papers in Honours of Maurizio Tosi for His 70th Birthday. BAR International Series, 2690, Oxford, 665-676.

Sajjadi, S.M.S., and H. Moradi, 2014. Excavation at Buildings Nos.1 and 20 at Shahr-i-Sokhta. *International Journal of the Society of Iranian Archaeologists*, 1/1, Winter-Spring 2014, 77-90.

Silver, I., 1969. The ageing of domestic animals. In D. Brothwell and E.S. Higgs (eds.), *Science in Archaeology*, London, 283-302.

Swindler, D.R., 2002. *Primate dentition. An introduction to the teeth of non-human primates*. Cambridge Studies in Biological and Evolutionary Anthropology, Cambridge.